



PATIENT

Bandit Ethier

SPECIES

Canine

BREED

Boxer

SEX

Male Neutered

AGE

4.17.12

WEIGHT

81lbs

INTERPRETED BY

Maggie Machen Lamy,
DVM, DACVIM
(Cardiology)

HOSPITAL NAME

Everhart Veterinary
Hospital

REFERRING VET

Dr. Key

INVOICE

23669

DATE

4.14.22

PRESENTING CLINICAL SIGNS

History: Pet presented for wellness exam. Pet has a slower heartbeat 75-80bpm with arrythmia.

- Blood pressure: 162mmHg,162mmHg & 160mmHg.
- Sedation used: Not required to complete full diagnostic ultrasound.
- Pertinent previous ultrasound results: No previous.
- STAT: Not requested
- Imaging performed by: Andi Parkinson, RDMS.

ELECTROCARDIOGRAPHIC FINDINGS

A six lead ECG is available at both 25 and 50mm/s; 5mm/mV. The average heart rate is 110bpm (range 83-150bpm). The rhythm is sinus in origin, with a p for every QRS complex and vice versa. The P wave morphology is positive with a normal dimension. Normal PR. The QRS morphology is positive with normal dimension. MEA is normal. Ventricular arrythmias appreciated throughout; singles, couplets, triplets and a brief salvo of VT (heart rate 200bpm). No supraventricular premature arrythmias appreciated.

ECG diagnosis: Respiratory sinus arrythmia with maglinant ventricular arrythmias.

ECHOCARDIOGRAM FINDINGS

2D, m-mode, color flow and doppler imaging is available. The mitral valve appears normal in form and function, with no obvious prolapse into the left atrial lumen. No MR seen. Normal left atrial dimension. Normal LV diameter with adequate myocardial function. Normal LV wall thickness. The tricuspid valve appears normal in form and function. No overt evidence of pulmonary arterial hypertension or right heart compensation, however right heart is prominent. No tricuspid regurgitation. The aortic valve is normal in morphology and mobility. No subvalvular ridge present, mildly increased velocity. No aortic insufficiency. Normal pulmonic valve with no pulmonic insufficiency seen. No pericardial or pleural effusion noted. No obvious cardiac tumors. Irregular rhythm noted throughout the examination.

CARDIAC CHART

CANINE CARDIAC PARAMETERS	MR VMAX (m/s)	TR VMAX (m/s)	LA/AO (Boon method)	LA/AO (Heart Base; Swe)	FS (%)	EF (%)	EPSS (cm)
NORMAL PARAMETER	4.5-5.5	<2.7	1.3	<1.6	28-40	40-100	<0.6
PATIENT	NA	NA	NM	1.38	29	56	NM
CANINE CARDIAC PARAMETERS	HR (BPM)	AV VMAX (m/s)	PV MAX (m/s)	BODY WEIGHT (kg)	LA 2D short axis Base view (cm)	LVIDd Avg; 2D and m-mode short axis (cm)	LVIDs Avg; 2D and m-mode short axis (cm)
NORMAL PARAMETER	50-100	0.7-1.7	0.7-1.6	BELOW	BELOW	BELOW	BELOW
PATIENT	110	2.0		36.7	3.0	4.1	2.9
*Normal chamber parameters expressed as a mean value (SD)				3	1.27 (5.3)	2.46 (2.46)	1.36 (5.5)
BODY WEIGHT DEPENDENT PARAMETERS				5	1.40 (4.5)	2.74 (5.2)	1.60 (4.7)
<i>*Note: All measurements based upon multi-modal images and methods. An average value is reported.</i>				10	1.50 (3.8)	3.27 (3.5)	2.06 (3.1)
				15	1.83 (2.0)	3.71 (2.4)	2.43 (2.1)
				20	2.02 (1.9)	4.14 (2.2)	2.80 (2.0)
				25	2.18 (2.4)	4.48 (2.9)	3.10 (2.5)
				30	2.33 (3.3)	4.83 (3.9)	3.39 (3.4)
				35	2.48 (4.3)	5.17 (5.0)	3.69 (4.5)
				40	2.62 (5.2)	5.48 (6.1)	3.96 (5.4)
				50	2.88 (7.1)	6.07 (8.3)	4.46 (7.4)

Adapted from June Boon, Veterinary Echocardiography, 1998
Rishniw M and Hollis NE, J Vet Intern Med 2000; 14:429-435
Hansson et al, Vet Rad and Ultrasound 2002
Bonagura et al. Echocardiography: principles of interpretation, Vet Clin North Am 15:1177, 1995

INTERPRETATION OF THE FINDINGS & FURTHER RECOMMENDATIONS

The cardiac structure and function are essentially normal in this patient. There is mild right heart prominence in some views, however this is angle dependent and may be a normal variant. The left heart dimensions are normal, and the systolic function considered adequate for a large breed dog. No valvular insufficiencies were noted, and no structural issues identified.

Frequent ventricular premature contractions were confirmed, in addition to a brief run of ventricular tachycardia. VPCs are generated from abnormal conductive or fibrotic tissue in the ventricles of the heart muscle, and even frequent single VPCs will often cause no clinical signs in dogs. When sustained however, ventricular tachycardia can lead to symptoms such as lethargy and collapse.

VPCs are a very non-specific finding. They can be primary in origin (such as ARVC), be secondary to significant cardiac disease (not present in this study) or be extra-cardiac in origin; i.e., due to pain, stress, inflammation, cancer, GI disease, DIC/sepsis, etc. In a senior Boxer, there is high suspicion for ARVC (most common age of onset 6-8yo, often asymptomatic). ARVC can occur with or without systolic dysfunction and structural issues, however this should be monitored going forward for any progressive issues. It is always reasonable to rule out other differentials for VPCs (AUS, tick titers, troponin, etc.) however suspicion is low given the signalment of the patient. Unfortunately, there is always an elevated risk for collapse and sudden death in any arrhythmic patient, and even on medications this risk unfortunately still persists. ARVC carries a HIGHLY variable prognosis, with some dogs able to remain asymptomatic for extended periods of time, and others developing exercise intolerance, syncopal episode, and refractory arrhythmias/sudden death imminently.

Based strictly upon the amount of arrhythmia present on the available ECG in this asymptomatic dog, anti-arrhythmic therapy is indicated. This is based upon the frequency of VPCs, in addition to couplets and a run of VT. Sotalol is typically the first medication used; however, the patient has a low resting heart rate making Mexiletine a safer choice. Follow up is advised, as dual therapy may be necessary. The low resting heart rate likely reflects high vagal tone and causes of high vagal tone can be considered, such as neurologic, respiratory or GI disease. Once Mexiletine is on board, an extended time 6 lead ECG and/or **holter monitor** is a reasonable next step to allow monitoring of the rhythm throughout 24 hours of a normal day to ensure good rhythm control.

Fish oil supplementation is recommended for dogs with arrhythmias (1000mg of omega 3 and 6 once to twice daily as tolerated).

Anesthetic risk is considered moderate. Avoid ketamine, telazol, Dexdomitor (or other alpha-2 agonists) and acepromazine. Recommend having lidocaine CRI available for use in the event of worsening ventricular arrhythmias under anesthesia (CRI 50–75mcg/kg/min).

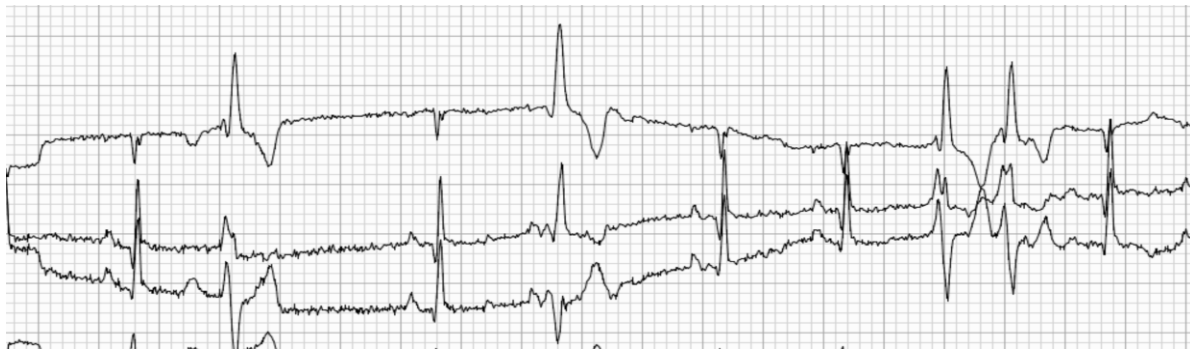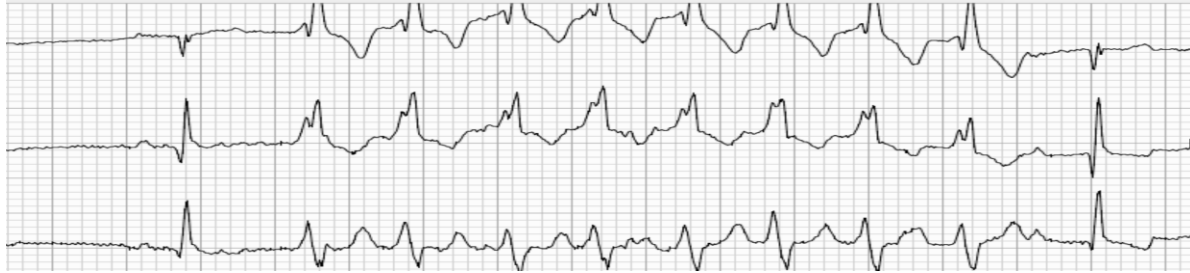
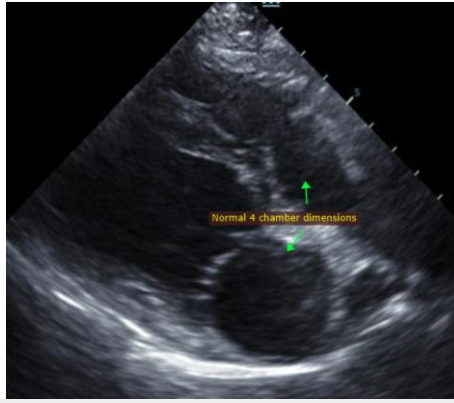
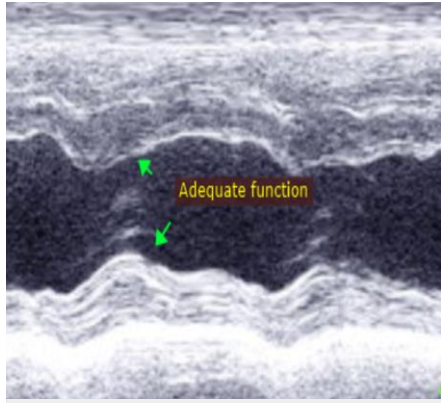
Monitor at home for collapse, exercise intolerance, and/or lethargy. Anesthesia is not recommended until good arrhythmic control is achieved. Lifelong mild to moderate activity restriction is advised.

PLAN

Institute mexiletine 5-7mg/kg PO q8h (available in 150 and 250mg capsules). Recheck ECG in 1-2 weeks to assess response (goal is significant reduction in ectopy without a significant change in underlying sinus rate). Consider holter at this time if desired.

Recheck ECG and echocardiogram is recommended in 6 months to determine progression/control, sooner if any development of associated clinical signs.

IMAGES



The information and recommendations provided are based on the images presented by the referring veterinarian. No evaluation can be communicated regarding pathology that was not visible in the image/video clips provided.

Thank you for this referral. This report was generated using transcription software, and minor dictation errors may be present. If the clinical or image interpretation does not parallel your findings or if I can be of any further assistance, please contact me.

Maggie Machen Lamy, DVM
Diplomate of the American College of Veterinary Internal Medicine (Cardiology)
info@sonopath.com